Pulmonary manifestations in patients with AIDS

Cristina Afione[1], Alejandra Della Sala[2], Laura Frank[3]

Resumen

El HIV produce una infección crónica que conduce a una severa inmunodepresión. El individuo infectado desarrolla un HIV sintomáticos que, sin tratamiento, progresa a sida, con una alta incidencia de infecciones oportunistas (IO) o enfermedades malignas agregadas.

El pulmón es uno de los órganos más afectados en el huésped inmunocomprometido por causas infecciosas o neoplásicas.

El tipo de afección pulmonar que desarrollarán estos pacientes depende del estadio de la enfermedad, el cual se determina, por lo general, sobre la base del recuento de linfocitos CD4.

La introducción de una terapia combinada de antiretrovirales y antibióticos profilácticos ha producido cambios que se manifiestan en la reducción del número de infecciones por agentes patógenos comunes más virulentos y un aumento simultáneo de la morbilidad debido a agentes menos virulentos.

Para realizar un diagnóstico más certero del tipo de enfermedad es importante tener en cuenta los factores de riesgo del paciente y el medio por el que se adquirió la infección por HIV.

Las imágenes, siempre basadas en la clínica, son una herramienta fundamental en el diagnóstico de las enfermedades pulmonares en pacientes con sida sintomático. Permiten reconocer el patrón radiográfico que suelen tener las diferentes IO y neoplasias, hacer el diagnóstico diferencial de las patologías posibles y monitorear la respuesta al tratamiento.

Se muestran radiografías simples y Tomografía Computada (TC) de las siguientes patologías: neumonía y bronquitis bacterianas; infecciones por nocardia, rodococcus equi, bartonella henselae, micóticas, micobacterianas, virales y parasitarias; neoplasias y enfermedades no infecciosas ni malignas.

Palabras clave. Pacientes inmunocomprometidos, HIV, neumonía bacteriana, bronquitis bacteriana, infecciones virales, citomegalovirus, infecciones micóticas, Pneumocystis jiroveci, TBC, nódulos pulmonares en HIV, sarcoma de Kaposi, linfoma

Abstract

The HIV virus causes a chronic infection that leads to severe immunosuppression. The infected individual develops symptomatic HIV, which, untreated, progresses to AIDS, with a high incidence of associated opportunistic infections (OI) or malignancies.

The lung is one of the most affected organs in the immunocompromised host, for infectious or neoplastic causes.

The type of pulmonary condition to be developed by AIDS patients will depend on the stage of disease, which is generally determined based on the CD4 lymphocyte count.

The introduction of combination anti-retroviral therapy and the use of prophylactic antibiotics have resulted in changes that are evidenced by a reduction in the number of infections caused by more virulent traditional pathogens and a simultaneous increase in morbidity due to less virulent organisms.

In order to make an accurate diagnosis of the type of disease it is important to consider the patient's risk factors and how the patient has acquired HIV infection.

Imaging, always based on clinical information, is an essential tool in the diagnosis of pulmonary diseases in patients with symptomatic AIDS. It makes it possible to recognize the radiographic pattern of the various OIs and neoplasms, to make a differential diagnosis of potential diseases and to monitor the response to treatment.

Plain radiographs and computed tomography (CT) scans of the following conditions are shown: bacterial pneumonia and bronchitis; infections caused by nocardia, rodococcus equi, bartonella henselae; fungal, mycobacterial, viral and parasitic infections; neoplasms, and non-infectious and non-malignant diseases.

Keywords. *Immunocompromised patient, HIV, bacterial pneumonia, bacterial bronchitis, viral infection, cytomegalovirus, fungal infection, Pneumocystis jiroveci pneumonia, pulmonary tuberculosis, pulmonary nodules in HIV, Kaposi sarcoma, lymphoma.*

INTRODUCTION

AIDS has been responsible of about 20 million deaths since the first case was identified in 1981. Since then, the number of HIV-infected subjects has been increasing worldwide and it is currently estimated at 37.8 million.

The HIV virus causes a chronic infection that leads to severe immunosuppression, which takes 2 to 3 years to develop in some individuals, while others remain free of disease for up to 10 to 15 years. The infected individual develops symptomatic HIV, which, untreated, progresses to AIDS, with a high

[1] Head
[2] Deputy Head
[3] Computed Tomography Coordinator at the Diagnostic Imaging Department of Hospital Juan A. Fernández, CABA.

incidence of associated opportunistic infections (OI) or malignancies.

The lung is one of the most frequently involved organs in the immunocompromised host, for infectious (75%) or neoplastic (25%) causes [1] [2].

A wide spectrum of pulmonary infectious diseases affecting AIDS patients is an important cause of morbidity and mortality, since almost 70% of patients develop a respiratory complication in the course of their disease.

This pulmonary condition results from the progressive impairment of the immune system, both at cellular and humoral levels, associated to the exposure of the respiratory system to the environment.

GENERAL CONSIDERATIONS

The host's response to infection is generated by lymphocytes which, acting as memory cells, lead the host's inflammatory response by recruiting and activating other immune effector cells (monocytes and macrophages), which attack the invading pathogen [3].

As disease progresses, the number of T lymphocytes decreases and the risk of developing opportunistic infections and malignancies increases [4].

Alveolar macrophages phagocytize and degrade organisms invading the lung. Their function is impaired in patients with AIDS and malignancies.

The type of pulmonary condition developed in AIDS patients will depend on the stage of disease, which is generally determined based on the CD4 lymphocyte (T-helpers) count [4]. This value is used routinely as the best predictor of disease progression and clinically to institute prophylactic therapy for OI.

The CD4 count is an excellent indicator of the degree of immunocompromise and of the risk of an HIV-infected patient's risk of developing an opportunistic infection (OI) or neoplasm, as there is a close relationship between the CD4 lymphocyte count and the likelihood of developing certain pulmonary conditions [3].

Normal values for CD4 lymphocytes range between 800 and 1,000 cells/mm^3.

When CD4 count is above 500 cells/mm^3, the risk of developing pulmonary disease in HIV-positive patients is similar to that of the general population. Below this level, specific OIs or neoplasms occur more frequently within various ranges of the CD4 lymphocyte count. Knowledge of the CD4 lymphocyte count is useful in limiting differential diagnoses at the time of diagnosing a potential condition in the patient being evaluated.

Chart 1 shows the prevalence of pulmonary diseases according to CD4 counts [1] [4] [5].

EPIDEMIOLOGY

Recently, there have been changes in the presentation and epidemiology of thoracic manifestations of AIDS, as a result of the introduction of a combination of anti-retroviral therapy and prophylactic antibiotics. These changes are evidenced by a reduction in the number of infections caused by more virulent traditional pathogens and a simultaneous increase in morbidity due to less virulent organisms.

For this reason, there is a reduction in the number of cases of Pneumocystis jirovecii (PJP) pneumonia and in the number of cytomegalovirus (CMV) and Mycobacterium avium complex (MAC) infections [6].

Another consequence is the coexistence of different infectious agents, which is seen in 10.5% of cases (the most common is Pneumocystis jirovecii and Cryptococcosis), or the simultaneous association of infectious and neoplastic disease (for example cytomegalovirus pneumonia and Kaposi's sarcoma).

There have also been changes in the population groups affected. Incidence is increasing in women and children, while the percentage of cases in homosexual and bisexual men is decreasing [6].

PULMONARY INVOLVEMENT IN AIDS

In order to make an accurate diagnosis of the type of disease, it is important to consider the patient's risk factors and how the patient has acquired HIV infection; for example, a similar radiographic pattern may lead to suspect Kaposi's sarcoma in homosexual or bisexual men and their partners; bacterial pneumonia in intra-

Chart 1: Prevalence of pulmonary diseases according to the CD4 count.

CD4	PROBABLE DISEASE
< 500 cell/mm^3	Bacterial pneumonia; Tuberculosis (TB)
< 200 cell/mm^3	Pneumocystis jiroveci; disseminated TB; toxoplasmosis
< 100 cell/mm^3	Kaposi sarcoma; non-Hodgkin lymphoma
< 50 cell/mm^3	Atypical mycobacteria; disseminated fungal infection; cytomegalovirus

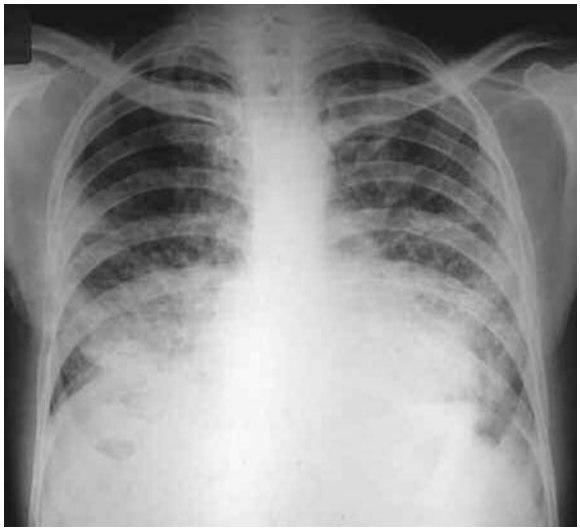

Fig. 1. Bacterial pneumonia on plain radiograph: patchy parenchymal infiltrates.

Fig. 2. Pseudomona pneumonia on plain radiograph: parenchymal infiltrate on right upper lobe, with cavitating lesions and bronchial walls thickening.

venous drug abusers (IVDA) or fungal infections in patients with neutropenia or on steroid therapy.

It is also important to obtain information about preexisting conditions unrelated to HIV infection (e.g., asthma, smoking, bronchogenic carcinoma) that may further complicate the respiratory condition being evaluated.

In addition, knowledge of the patients' medical history is also required, especially if they have had previous pulmonary conditions related to their immunodeficiency, as some OI recur frequently (for example, bacterial and Pneumocystis jirovecii pneumonias).

THE ROLE OF IMAGING

Imaging, always based on clinical information, is an essential tool in the diagnosis of pulmonary diseases in AIDS patients, as they contribute to confirm the presence of thoracic pathology in symptomatic patients [7]. This make it possible to recognize the radiographic pattern of the various OIs and neoplasms and/or the combination of radiographic signs that may occur, as well as to make a differential diagnosis of potential diseases and monitor the response to treatment [1].

When there is a suspicion of pulmonary disease, the first test to be performed is a chest radiograph. Computed tomography (CT) is used when the chest radiograph is normal or findings are nonspecific or uncertain.

CT scans provide a more accurate diagnosis, allowing clarification of findings identified on plain radiograph, determination of the extent and radiographic pattern of disease; evaluation of the mediastinum, evidencing the presence of lymph node enlargement; staging of malignant disease or re-staging post therapy; biopsy planning, including identification of representative lesions and the choice of the best technique (percutaneous, thoracoscopy, open-lung biopsy) and imaging guidance for diagnostic and/or therapeutic procedures.

CAUSES OF PULMONARY DISEASE IN AIDS PATIENTS

a) Infectious: bacterial, fungal, mycobacterial, viral or parasitic.
b) Neoplastic: Kaposi's sarcoma, lymphoma, carcinoma
c) Non-infectious and of no neoplastic etiology: lymphocytic interstitial pneumonitis, bronchiolitis obliterans, nonspecific interstitial pneumonitis.

a) Infectious processes

In infectious processes, the three principal radiographic patterns are: localized, patchy, segmental or lobar consolidation; nodules with or without cavitation and diffuse interstitial infiltrates [7]. Any of these patterns may be associated with lymph node enlargement or pleural effusion.

For detecting lung parenchyma abnormalities, CT scan is 53% sensitive, 63% specific, with 70% true negatives and 59% true positives.

- ***Bacterial infections***

Bacterial infections occur in 5 to 30% of HIV-positive patients. They may develop in the early stages of disease (CD4 count >500 cells/mm3), or at any time during the course of disease, in inverse proportion to CD4 decrease.

Bacterial pneumonia and bronchitis have become more frequent than PJP, which was the most common pneumonia before the advent of prophylactic antiviral therapy.

Bacterial pneumonia

Incidence of bacterial pneumonia is five times greater in HIV-positive population than in otherwise similar but HIV-negative population; the incidence of pneumococcal disease, including pneumonia, is 10 times greater and the development of pneumococcal septicemia is 100 times greater [6].

The clinical presentation (fever, cough, purulent sputum) is generally the same as in the HIV-negative population and it usually follows a similar clinical course, although there is an increased tendency to rapid progression: cavitation, parapneumonic effusion and empyema formation [8].

Etiologic diagnosis of bacterial infection in HIV-positive or AIDS patients is based on clinical presentation, supporting radiographic findings, sputum smears and cultures.

Bronchoalveolar lavage (BAL) has been effective to establish diagnosis with sensitivities above 80% when samples were obtained before the initiation of antibiotic therapy. Blood cultures should be routinely performed in these patients because of the high incidence of bacteremia [5].

Bacterial pneumonia is most commonly caused by Streptococcus pneumoniae and Haemophilus influenzae (25% of infections in general), and less commonly by Pseudomonas aeruginosa, Streptococcus viridans and Staphylococcus aureus.

Patchy, (Fig. 1), lobar or segmental consolidation appears on plain radiograph [7], although an increased frequency of interstitial infiltrates has been recently reported; cavitation within consolidation, when the infection is caused by gram-negative organisms, as for example pseudomonas (Fig. 2) and multiple cavitating nodules in the case of septic embolism, especially in IVDA.

In hospitalized patients with pneumonia due to Streptococcus pneumoniae, the most common radiographic finding is lobar consolidation involving single or multiple lobes, independently of HIV status [9].

CT scan accurately localizes areas of consolidation, seen as parenchymal opacities with bronchovascular structure effacement, air bronchogram and cavitations.

CT scan is also helpful in accurately defining the number and size of nodules caused by septic embolism, as well as their distribution, which can be peripheral with lower lobes predominance. Visualization of the feeding vessel leading to the nodule, "feeding vessel sign", indicates hematogenous dissemination [7] (Fig. 3 and 4).

Bacterial bronchitis

In AIDS patients, even in nonsmokers (CD4 count < 100 cell/mm3), there is a higher incidence of bronchitis, bronchiolitis and bronchiectasis due to pyogenic airways infection as compared to immunocompetent persons [3].

Acute bacterial bronchitis is not evident on plain radiograph, but linear images with a peribronchial distribution may be occasionally seen, leading to suspicion of bronchiectasis.

CT findings of bronchitis include bronchial wall thickening, resulting from bronchial or peribronchial inflammation (Fig. 5) or dilation of the bronchial lumen, when there is bronchiectasis.

The characteristic findings of bronchiolitis are ill-defined centrilobular densities of about 3 mm, representing impaction of bronchiole with inflammatory material. In HIV-positive patients, these images are often symmetrical, affecting lower lobes. Air-trapping areas (mosaic perfusion) may also appear, caused by small airways disease, obtained on expiratory images (Fig. 6).

Nocardiosis

The etiological agent of nocardiosis is Nocardia asteroides, currently considered as a bacterium (formerly thought to be a fungus). Infection appears with low CD4 counts (<200 cell/mm^3) [8].

Both plain radiograph and CT scan show the most common presentation, i.e. alveolar consolidation in a single or multiple lobes. Solitary pulmonary masses, reticulonodular infiltrates and pleural effusion may also be identified; cavitation is a common feature within masses or areas of consolidation (Fig. 7).

Diagnosis depends on the demonstration of the organism on sputum culture, lavage or biopsy.

Rodococcus equi and Bartonella henselae

These pathogens cause infectious processes very characteristic of AIDS.

The former is a gram-positive bacillus, affecting patients with CD4 count <200 cell/mm^3) [2]. It causes pneumonia of subacute onset, with upper lobe predominance, often with thick-walled cavities. It is usually associated with pleural effusion or empyema [8], extrapulmonary abscess and mediastinal invasion [2].

The bacillus Bartonella henselae causes bacillary angiomatosis, a treatable infection that occurs almost exclusively in HIV-positive patients. It results in areas of vascular proliferation that may affect the airways and lung parenchyma. Kaposi's sarcoma-like vascular skin lesions are present.

In the lung, it manifests as solitary or multiple nodules, of varying size ranging from 1 mm to several centimeters; mediastinal lymphadenopathy is a common finding. With both lesions, there is an intense enhancement on IV contrast-enhanced CT, which reflects the marked vascularity of these lesions. Pleural effusion may be present [6].

- ***Fungal infections***

Pulmonary fungal infections in AIDS patients are uncommon (less than 5%), even in markedly immunocompromised patients.

This is due to the fact that the main cells involved in host defense in fungal infection are neutrophils, not T-lymphocytes, and alveolar macrophages in the lung, mainly for Aspergilus and Candida [5].

Fig. 3. Septic embolism on HRCT: peripheral nodular opacities, one of them with cavitation (arrow).

Fig. 4. Septic embolism on HRCT: peripheral nodular opacities, with "feeding vessel sign" (arrow)

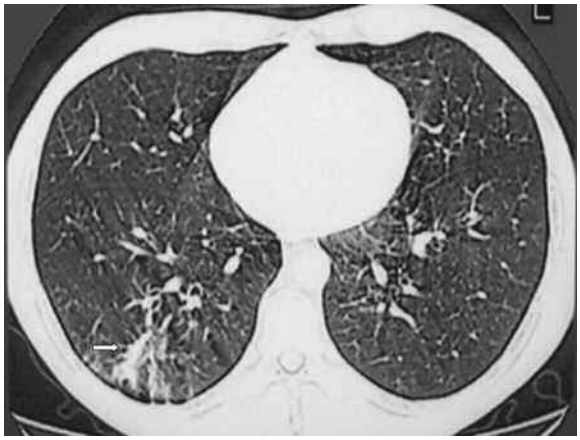

Fig. 5 Bronchitis on HRCT: thickening of bronchial wall.

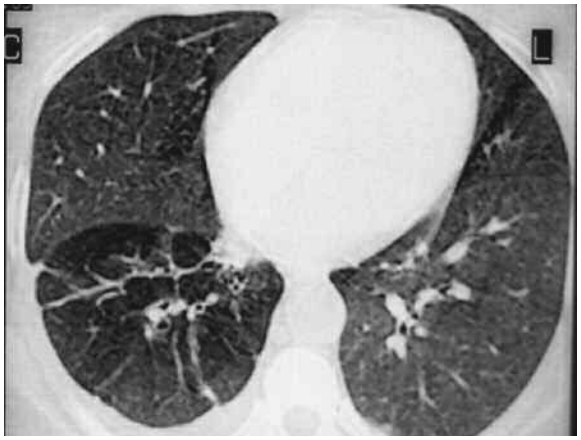

Fig. 6 HRCT expiratory image of small airway disease: thickening of bronchial wall and air-trapping areas on right lower lobe.

Pneumocystis jirovecii

Unlike other fungal infections, the infection caused by PJP is common, with an incidence of 23.8%.

PJP is an obligate extracellular pathogen that in 1988 was reclassified as a fungus within the Ascomycetous fungi [10].

It resides mainly in the lung alveoli, but it can also be found in other tissues.

Primary infection usually occurs in childhood and is asymptomatic. Serologic studies have shown that 65-100% of children have antibodies to PJP by the time they are 2-4 years of age [11]. The pathogen remains latent and may be reactivated as a consequence of severe cellular immunosuppression, as in AIDS [10].

PJP is more common in homosexual patients than in IVDAs and it occurs more frequently in white males, independently of how the disease is acquired.

Despite the decrease in the incidence of PJP as a result of prophylactic therapy, a high percentage of patients (60%) continue to experience at least one episode of pneumonia during the course of disease. It usually occurs with CD4 counts < 200 cell/mm^3 [12].

Clinical symptoms of PJP pneumonia include fever, nonproductive cough, dyspnea and hypoxia [12] [13]. Acute dyspnea with pleuritic chest pain may indicate the development of a pneumothorax [11].

Plain radiographs may be normal in 10% of cases [1] [7] [12] but High-Resolution Computed Tomography (HRCT) may reveal ground-glass infiltrate. In addition, radiographic findings may include bilateral, diffuse, often perihilar reticular opacities, poorly-defined ground-glass opacities in the upper lobes [10] [12] [14] (Fig. 8).

Cystic lesions are present in about 10% of cases and may be responsible for the production of spontaneous pneumothorax [8] [14]. These lesions most commonly occur in patients receiving prophylaxis with aerosolized pentamidine and trimethroprim-sulfamethoxazole (TMS) [13] [15].

Cysts are thin-walled, do not contain any material and are predominantly apical or subpleural in location, although they me be distributed throughout the lung parenchyma [12] (Fig. 9 and 10). They may resolve

Fig. 7: Nocardiosis on plain radiograph: confluent infiltrate with cavity on right lower lobe.

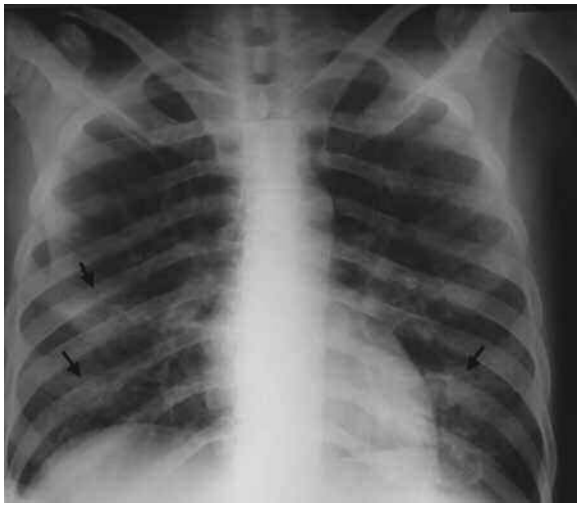

Fig. 8: PJP on plain radiograph: bilateral reticular interstitial infiltrate and ground-glass areas (arrows).

completely on adequate therapy, or occasionally persist as sequel [6].

Rare presentations (frequency below 5%) include focal or asymmetric areas of consolidation, cavitating nodules or masses, necrotizing vasculitis, endobronchial lesions, granulomas and calcified lymph nodes, miliary pattern mimicking tuberculosis [11], lymph node enlargement or pleural effusion [12].

Development of a solitary pulmonary nodule may be owing to a granulomatous response in less immunocompromised patients.

HRCT scan shows diffuse ground-glass opacity (alveolitis) defined as increased diffuse attenuation with preservation of bronchial and vascular markings (Figs. 11 and 12). This finding is highly suggestive of PJP [12]. It may have a geographic distribution because of selective involvement of secondary pulmonary lobules.

In the early stage, HRCT shows reticular infiltrates within the ground-glass areas, for infiltration of enlarged lymph nodes in interlobular septae [13].

Other findings include diffuse interstitial fibrosis or sequellar emphysema, even after adequate treatment, and cystic lesions.

Diagnosis requires microscopic examination of the sputum, bronchoscopy with bronchoalveolar lavage or biopsy of lung tissue, because this pathogen may not be cultured [1] [12].

Following adequate therapy, radiographic abnormalities usually worsen during the first few days of therapy and in more severe cases they may progress to air space consolidations. Deterioration may continue for 7-10 days of treatment, and then abnormalities start to resolve [11]. However, abnormalities may persist for a long time, due to interstitial fibrosis.

Other fungal infections affecting patients with AIDS in our setting include Aspergillosis, Criptoccocosis and Histoplasmosis.

Aspergillosis

This infection is caused by Aspergillus fumigatus, generally with CD4 count < 50 cell/mm^3.

There are three patterns of disease: invasive aspergillosis, necrotizing tracheobronchial aspergillosis and mycetoma or aspergilloma [6].

Invasive aspergillosis is the commonest form and it is characterized by tissue necrosis and granulomatous inflammation similar to tuberculosis.

Findings on plain radiograph and CT scan include nodules and areas of lung consolidation in upper lobes, with or without cavitation. In general, there is a single cavity, although multiple cavities may occur (Fig. 13). Lesions progress slowly over months or years.

Angioinvasive aspergillosis occurs almost exclusively in immunocompromised patients. The characteristic CT findings consist of a halo of ground-glass infiltrate surrounding lesions similar to those described above, corresponding to hemorrhagic infarcts resulting from vascular invasion [16].

Necrotizing tracheobronchial aspergillosis produces nodular thickening of the tracheal and bronchial walls owing to plaque-like lesions. An uncommon form of infection is that confined to the bronchi, with the formation of pseudomembranes that cause bronchial obstruction, resulting in atelectasis. Plain radiograph is often normal; bronchiolitis is characterized on HRCT by the presence of centrilobular nodules and linear or nodular opacities giving an appearance resembling a "tree-in-bud" [13].

Mycetomas are a saprophytic form, with their primary manifestation being hemoptysis.

On plain radiograph and CT scan, mycetomas are characterized by the presence of a solid mass with soft-tissue opacity within preexisting lung cavities, generally due to previous PJP or TB.

The mass is separated from the wall of the cavity by airspace of variable size resulting in the "air crescent

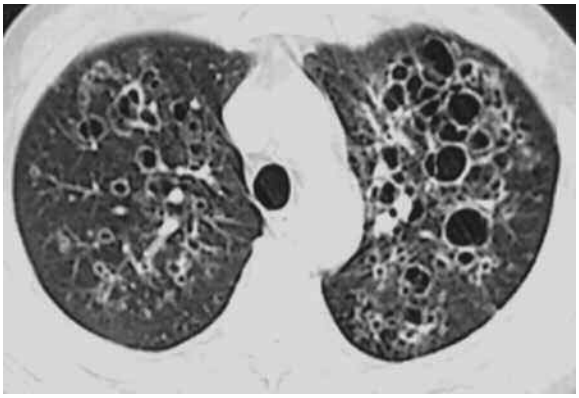

Fig. 9. Cystic PJP on HRCT: cystic images in upper lobe and bilateral peripheral small nodules.

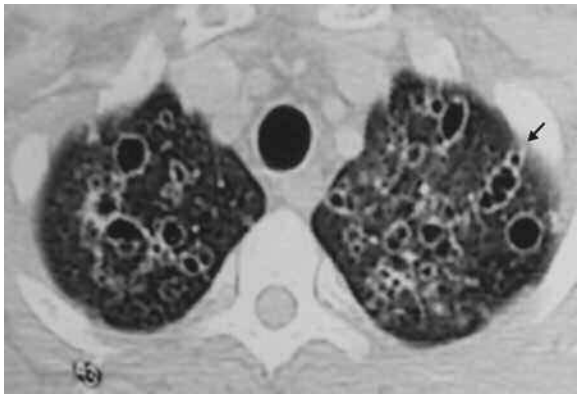

Fig. 10. Progressing cystic PJP on HRCT: cysts become confluent and extend to the periphery (arrow).

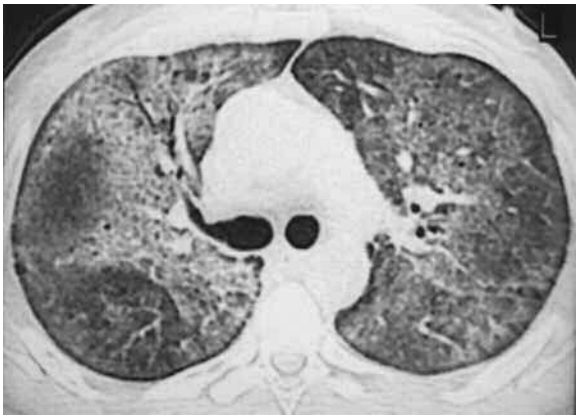

Fig. 11. PJP on HRCT: ground-glass patchy areas, of perihilar location in both upper lobes.

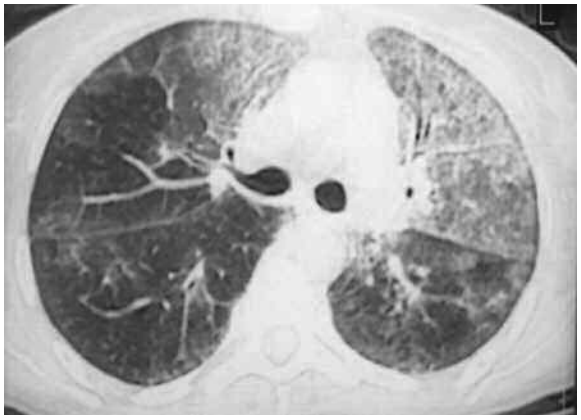

Fig. 12. PJP on HRCT: ground-glass infiltrate predominantly in both upper lobes.

sign" (a not pathognomonic sign) [16]. (Fig. 14 and 15).

Aspergillomas are usually associated with thickening of the cavity wall and adjacent pleura. Pleural thickening is an early sign that should lead us to suspect the initiation of the process, even before any mass becomes visible within an already known cavity.

Cryptoccocosis

This infection is caused by Cryptococcus neoformans, which enters the body via the respiratory tract.

The most common manifestation is meningitis, and the lung is involved in approximately 40% of cases.

In general, the pulmonary infection is silent, but it may cause dyspnea, cough and less frequently chest pain and hemoptoic expectoration. It often occurs with CD4 counts <100 cells/mm^3 [6].

The most frequent findings on plain radiograph and CT scan include reticular or reticulonodular interstitial infiltrates; less common manifestations include alveolar consolidation, ground-glass infiltrate, miliary nodules, mild pleural effusion and hilar and mediastinal lymph node enlargement [8] [13].

In patients with a diagnosis of pulmonary cryptococcosis, nodules, masses and consolidation are more frequent in localized disease, while interstitial infiltrates with pleural effusion may be indicative of disseminated extrapulmonary disease [17].

The diagnosis is established by the combination of a positive cryptococcal antigen test together with isolation of the organism by culture from sputum, bronchial lavages or biopsy [6].

Differential diagnosis with PJP, TB and pyogenic infections should be considered.

Histoplasmosis

This infection is caused by Histoplasma capsulatum. In highly endemic regions, the incidence of histoplasmosis is high. The fungus enters the body by inhalation; it is phagocytized by the reticuloendothelial system and rapidly spreads throughout the body [18].

Pulmonary disease may occur alone, or more commonly in association with disseminated disease, usually at pronounced levels of immunosuppression.

It manifests as fever, weight loss, cough and sometimes dyspnea.

Plan radiograph and CT scan show multiple small nodules, often less than 3 mm in diameter [13] (Fig. 16), irregular linear opacities with a diffuse distribution

Fig. 13: Invasive Aspergillosis on HRCT: confluent lesions of nodular appearance and peripheral nodules in right upper lobe.

Fig. 14. Aspergilloma on plain radiograph: thin-walled cavity with solid content in left upper lobe.

Fig. 15. Aspergilloma on CT: cavity with mycetoma (arrow).

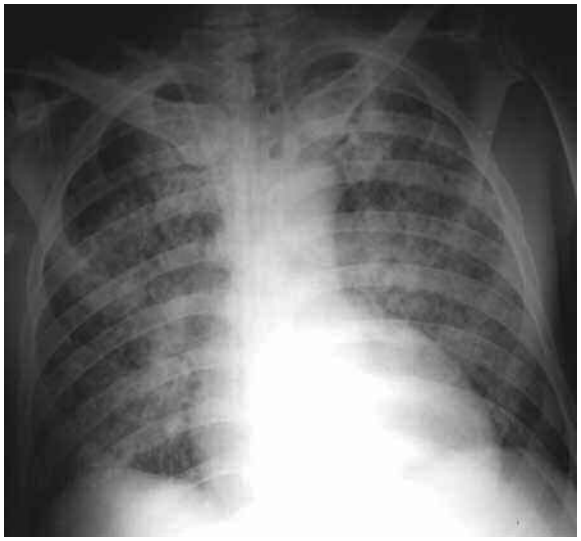

Fig. 16: Histoplasmosis on plain radiograph: multiple micronodules of bilateral and diffuse (miliary) location.

pattern and small pleural effusions [5].

Lung consolidation and hilar or mediastinal lymphadenopathy are infrequent.

In 40% of cases chest radiographs may be normal, even in patients with conspicuous pulmonary involvement [13].

As radiographic findings are non-specific, the diagnosis requires isolation of the organism from bronchial aspirate.

- ***Mycobacterial infections***

Tuberculosis (TB)

Mycobacterium tuberculosis remains one of the opportunistic agents that most commonly affect AIDS patients.

TB may be the first clinical manifestation indicative of HIV infection.

It is important to highlight that the incidence of TB in the AIDS population is 37.2%, 200 to 500 times greater than in the general population [5].

TB infection may accelerate the progression of HIV infection, as both increase concurrent OIs and decrease survival.

Although the course of TB in HIV-positive patients is more virulent, the response to treatment is often good.

Tuberculin test is positive in approximately one third of cases but BAL is positive in only 20%.

Clinical symptoms of TB pulmonary disease are similar to those caused by other mycobacteria: fever, night sweats, weight loss, productive cough, dyspnea, central chest pain and sometimes hemoptysis.

Radiographic findings of TB depend on the degree of immunosuppression [1].

In early stages of HIV infection with high CD4 cell

counts (<500 cells/mm^3) we may find a similar pattern to that of reactivation of TB in the general population, namely, focal consolidation, at times with cavities in apical and posterior segments of upper lobes and apical segment of lower lobs, with pleural involvement.

In patients with advanced disease, with CD4 count below 200 cells/mm3, the most common presentation is a primary TB pattern with a tendency to hematogenous (miliary) spread and bronchopulmonary dissemination (consolidation) [19].

These lung alterations are present in 85% of cases and we can also find a high incidence of extrapulmonary involvement as lymphadenitis or multi-organ dissemination.

Plain radiograph commonly shows diffuse interstitial infiltrate (miliary) (Fig. 17), focal consolidation in the middle-lower lobes, solitary or multiple nodules, mediastinal and ipsilateral hilar lymphadenopathy in 25 to 90% of cases and pleural effusion in 20% of patients.

Less common findings include cavitary disease (Fig. 18) or normal radiograph. Patients with a normal radiograph and clinical suspicion of TB should be further investigated with the use of HRCT [19].

HRCT may demonstrate, apart from radiographic findings, miliary pattern, centrilobular branching nodules: "tree in bud" appearance and nodal enlargement with central necrosis.

Enlarged lymph nodes are not only observed in primary disease but may also be characteristic of TB reactivation in AIDS.

On CT, lymphadenopathy manifests as low-density, necrotic nodules with peripheral enhancement on IV contrast administration. This finding is sufficiently specific to allow empirical therapy to be commenced.

In primary or post-primary TB, endobronchial disease may occur: bronchitis and bronchiolitis due to endobronchial spread of the infection. CT scan may show the typical "tree in bud" pattern resulting from inflammatory material impaction and small airways dilatation [5]. Bronchiectasis is common both in primary disease and in reactivation.

In patients on antiretroviral therapy, a radiographic pattern of post-primary TB is observed as a result of induced cell-mediated immunity, similar to that of the general population [19].

After adequate treatment, follow-up imaging demonstrates total resolution of findings. The lack of resolution or worsening of lesions suggests the presence of a superimposed OI.

***Mycobacterium avium* complex (MAC) infection**

MAC is an atypical mycobacterium for which the main portal of entry is the gastrointestinal or the respiratory tract. Patients with AIDS are at high risk for this infection, especially those with advanced disease, with CD4 counts below 50 cells/mm^3.

Although 35% of patients with AIDS develop MAC infection during the course of their disease, this infection is rarely considered as initial diagnosis because radiological findings are nonspecific: diffuse interstitial or alveolar infiltrates, hilar and mediastinal lymph node enlargement, in 6 to 20% of cases (Fig. 19), and rarely cavitation and pleural effusion [8].

A normal chest radiograph is common (more common than in TB) [20].

CT scan confirms radiographic findings and HRCT may detect, as in TB, the presence of a "tree-in-bud" pattern, air trapping areas and bronchiectasis for endobronchial involvement [21].

Extrathoracic disseminated infection and severe anemia generally occur (more commonly than pulmonary involvement), and these findings contribute to diagnosis [20].

The definitive diagnosis is made by isolating MAC from blood cultures or bone marrow aspirates.

***Mycobacterium kansasii* (MK) infection**

This infection causes symptoms similar to those of TB, although less virulent.

It occurs in patients with advanced immunosuppression (CD4 count < 50 cells/mm^3). Sixty to seventy-five percent of patients develop pulmonary disease, and up to 22% of patients develop pulmonary and extrapulmonary disease. Disseminated infection with no lung involvement occurs in one-fifth of cases.

Radiograph shows unilateral or bilateral alveolar infiltrates, predominantly in the upper lobes. Cavitation is common: 53% of cases. Hilar lymphadenopathy may occur (25%); interstitial infiltrates and pleural effusion are infrequent [5].

As with other mycobacteria, diagnosis requires isolation of the organism.

- ***Viral infections***

Viral infections are rare and are associated with marked immunosuppression.

Of the 8 types of human herpes viruses, 6 are associated with substantial morbidity in patients with AIDS. They include cytomegalovirus, herpes simplex virus type 1 and type 2, varicella zoster virus, Epstein-Barr virus and human herpes virus type 8.

Pulmonary infection by any of these viruses may manifest as diffuse interstitial pneumonitis, while herpes simplex virus may also produce focal necrotizing trancheobronchitis.

***Cytomegalovirus* (CMV) infection**

Isolation of CMV from respiratory secretions is very common; however, CMV rarely causes pulmonary conditions [22]. Recent studies suggest an increase in CMV pneumonitis resulting from the use of prophylaxis against PJP, the use of steroid therapy in a large number of AIDS-related diseases and longer life expectancy of severely immunocompromised patients [5].

CMV is more often found in combination with

Fig. 17.TB on plain localized radiograph: diffuse and bilateral micronodular infiltrate.

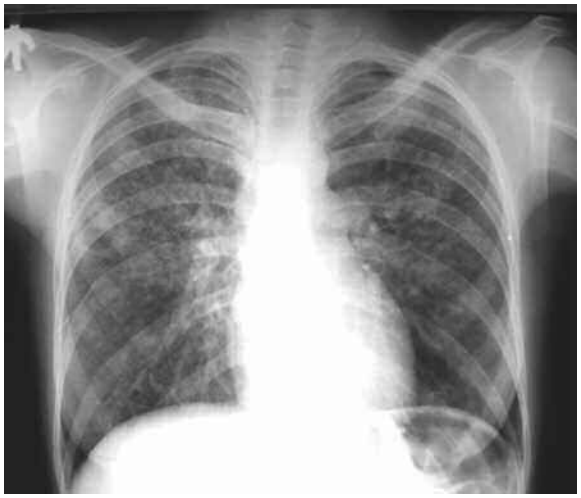

Fig. 18: Post-primary TB on plain radiograph: bilateral reticulonodular infiltrates, predominantly on the upper lobe with cavitation.

Fig. 19. Atypical Mycobacteria on plain radiograph: diffuse interstitial infiltrate with areas of alveolar involvement. Right paratracheal lymph node (arrow).

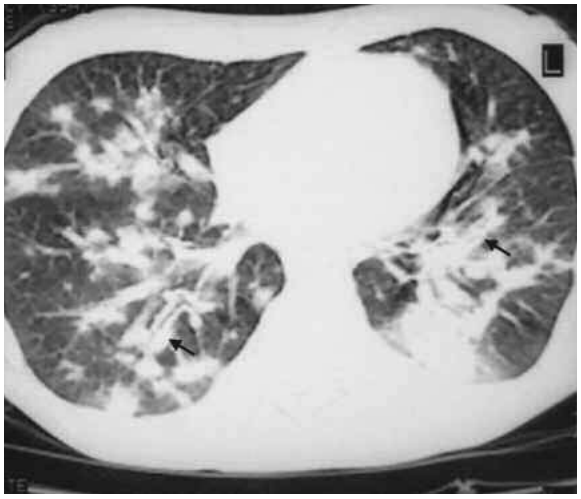

Fig. 20. Kaposi's Sarcoma on HRCT: peribronchial thickening and nodules of bilateral peribronchovascular distribution, mimicking air bronchogram (arrows).

other infections, particularly PJP. But according to the Centers for Disease Control (CDC), to be considered pathogen, CMV should be the only isolated agent [22]. It occurs in patients with CD4 levels below 50 cells/mm^3.

Plain radiographic findings include alveolar infiltrates initially in the lung periphery or interstitial and nodular infiltrates, which are perihilar and extend into the lower zones [23].

HRCT scan shows diffuse ground-glass attenuation, air-space consolidation, bronchial wall thickening or bronchiectasis, interstitial reticular infiltrate, nodules (>3 cm) or masses [6].

Radiologically it is very difficult to differentiate CMV from PJP. Other methods, such as lung biopsy, are needed. Diagnosis of CMV is made by identifying intranuclear inclusion bodies in the epithelial cells of bronchiole and alevoli [23].

Epstein-Barr Virus

Epstein-Barr Virus may cause lymphoproliferative disease of the lung, which manifests as multiple nodules of peribronchovascular or subpleural distribution.

- ***Parasitic infections***

Parasitic infections are rare and they occur in patients with advanced HIV disease.

The most common parasitic infections include toxoplasmosis, strongyloidiasis, cryptosporidium and microsporidium.

Radiological pulmonary findings of all these infections are non-specific.

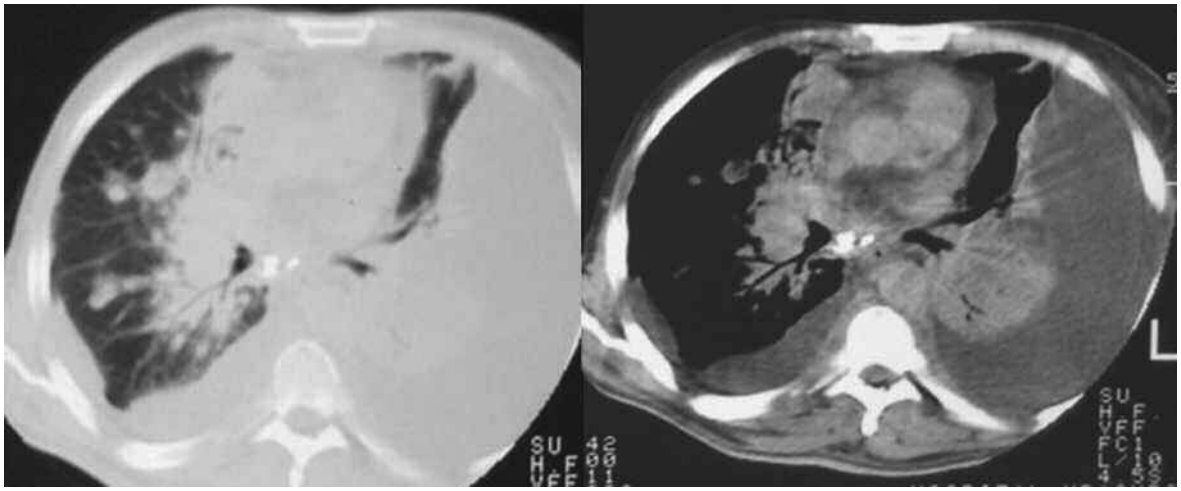

Fig. 21. Kaposi Sarcoma with bilateral pleural effusion on CT scan: a) pulmonary window: peribronchial thickening and nodules on the right side. B) mediastinal window: calcified subcarinal and right hilar lymph node enlargement.

b) Neoplastic disease

Kaposi's sarcoma (KS)

KS is the most common AIDS-associated malignancy. Before epidemiological changes, the incidence of this disease was 25%.

This is a lymphoproliferative process affecting almost exclusively adult homosexual or bisexual men and their partners, with a male / female ratio of 50 to 1 [5]. This low index of disease in women leads to initially suspect of an infectious etiology, resulting in late diagnosis [24].

The incidence of KS has been falling over years as a result of the use of antiretroviral therapy.

The course of this disease is variable; it may range from slowly progressive to aggressive.

Poor prognostic factors include the absence of cutaneous KS, previous opportunistic infections, CD4 cell count < 150 cell/mm^3 and the presence of leucopenia, anemia and large pleural effusions.

Survival in patients with CD4 count above 150 cell/mm^3 is approximately 3 years, while in those with CD4 count below 150 cell/mm^3, survival is 1 year.

The human herpes virus 8 has been identified as the most likely causal agent for KS, possibly in combination with other infectious factors [24].

The first clinical findings are mucocutaneous lesions, particularly on the trunk and extremities. They are nodules that measure 1-2 cm in diameter, and are raised and violaceous. Lesions increase in size and number as the disease progresses.

KS may affect the oropharynx, larynx, lung parenchyma, pleura, chest wall and gastrointestinal system, with extensive lymph node involvement.

Patients with pulmonary lesions usually do not have upper respiratory tract involvement.

Pulmonary involvement occurs in up to 50% of patients with epidemic KS and it is almost always preceded by cutaneous or visceral involvement. The tumor becomes more aggressive as immunosuppression increases [5].

Fig. 22 Lymphoma on CT scan: bilateral basal nodules of well-defined borders.

Symptoms of KS include cough, dyspnea, fever and less frequently hemoptysis; a similar presentation to that of PJP, with which differential diagnosis should be made.

Plain radiograph reveals peribronchovascular thickening, extending from the hila to the periphery as disease progresses. Then this thickening becomes nodular (1). Findings also include areas of consolidation, developing from coalescence of nodules. Middle and lower lobes are most commonly involved [5].

Kerley lines are also visualized, which are sometimes asymmetrical, reflecting tumor infiltration or edema secondary to lymphatic obstruction, pleural effusions, pericardial effusions and mediastinal

lymphadenopathy.

In final stages, ill defined nodules and interstitial infiltrates may be observed, representing thickening of the interlobular septae; this finding may be asymmetrical.

CT features are bronchial wall thickening, spiculated nodules 1 to 2 cm in diameter, thickening of the interlobular septae, which may be smooth or nodular (Fig. 20), unilateral or bilateral pleural effusion (35-50%) and hilar and mediastinal lymphadenopathy (16%), as advanced manifestation of disease (Fig. 21 a and b).

When there is airway involvement, CT reveals raised up lesions in the lumen. To confirm the presence of endobronchial lesions, bronchoscopy should be performed.

When evaluating patients with suspicion of intrathoracic KS, Nuclear Medicine scans are useful, as KS lesions demonstrate thallium uptake and no gallium uptake, while lymphoma is thallium and gallium positive, and infections are thallium negative and gallium positive.

Lymphoma

Lymphoma is the second most common malignancy in AIDS patients. The incidence of lymphoma in AIDS patients varies from 5 to 15% according to different studies; i.e. it is 40 to 100 times greater than that of the general population. It tends to occur at earlier ages and it is often diagnosed at advanced stages.

Thoracic involvement occurs in up to 10% of patients with AIDS-related lymphoma. It may be part of a systemic disorder involving multiple organ systems or, less frequently, it can arise as a primary pulmonary lymphoma corresponding to exclusive lymphomatous parenchymal involvement with no other organ involvement at diagnosis or within 3 months following diagnosis.

Table 1: Diagnostic trend according to radiological pattern.

	Normal X-ray	Diffuse interstitial infiltrates	Focal consolidation	Nodules or nodular infiltrates with/without cavity	Nodules	Cavitated nodules	Hilar or mediastinal lymphadenopathy	Pleural effusion
PJP	X*	X						
Mycobacteria	X	X*	X	X			X	X
Fungi	X	X	X	X**			X	
Pneumonia Bacterial			X					X***
Kaposi S.		X			X		X	X
Lymphoma					X			X*
NSIP		X						
LIP		X*						
Septic embolism							X	
Invasive Aspergillosis						X		
CMV		X	X	X				

* Rare / ** Cavitation is more common in cryptococcosis / *** In complication of bacterial pneumonia.

Table 2: Diagnosis of potential etiologies by size, distribution and morphological characteristics of the nodules.

	Nodule size	Distribution	Tree in bud	Cavity	Pleural lymphadenopathy	Air effusion	Space
Bacterial Infection	< 1 cm	centrilobular	yes	probable	Rare	Rare	Common
Mycobacterial infection	< 1 cm	centrilobular	yes	probable	hypodense with peripheral enhancement	very common	no
Kaposi S.	> 1 cm	peribronchovascular	no	no	probable	probable	no
Lymphoma	> 1 cm	nonspecific	no	no	probable	probable	no

There are three histological types of lymphoma, with the following characteristics:

Non-Hodgkin's lymphoma: this is the most common (70%); it occurs with CD4 count <100 cells/mm^3 and it has a high degree of malignancy.

Hodgkin's lymphoma: it is less common and of early onset; it occurs with CD4 >200 cells/mm^3 and it has a high degree of malignancy and aggressive behavior.

Burkitt's lymphoma: it is very rare and it is related to Epstein - Barr virus (EBV).

Imaging shows solitary or more commonly multiple (85.7%), well-defined nodules greater than 1 cm in diameter, which are often peripheral and predominantly present in the lung bases [25] (Fig. 22). Ten percent of nodules may cavitate after therapy. A well-defined solitary pulmonary nodule may also appear, being suggestive of lymphoma in a patient with AIDS. Pleural effusion is a common finding.

No prominent lymphadenopathy occurs, in contrast to lymphomas in the general population.

In the case of overlapping radiological findings, and in the absence of associated pleural effusion, the possibility of a primary pulmonary lymphoma should be considered [25].

A rare form of AIDS-related lymphoma exists, which has been described as body cavity-based lymphoma (related to B-cell proliferation due to long-term HIV infection stimulation) and described in association with herpes virus-8 infection. It presents as unilateral or bilateral pleural effusion, pericardial or peritoneal effusion and diffuse thickening of the parietal pleura in the absence of pulmonary lesions and enlarged lymph nodes.

Definitive diagnosis of lymphoma is made by transbronchial, transthoracic or open biopsy.

Lung carcinoma

It occurs in younger patients. At the time of diagnosis, it is at a more advanced stage [5] and has a shorter survival time than in the general population.

It is thought that the increased incidence may reflect an increased exposure to risk factors such as cigarette smoking, rather than the HIV infection itself or oncogenic perpetuation in the immunocompromised patient.

Cell types are similar to those found in HIV-negative patients, and they are mainly adenocarcinoma. They are poorly differentiated and grow rapidly.

The most common radiographic and CT presentation includes a central or peripheral pulmonary mass associated with mediastinal adenopathy, atelectasis and pleural effusion.

Late diagnosis of neoplasms is common because of coexisting intercurrent infective processes, which result in non-specific radiological appearances.

There is predisposition for peripheral tumors to occur in the upper lobes in patients with a history of TB or PJP, which suggests that post-inflammatory scarring may be of relevance as possible etiologic factor of neoplasm in the HIV-positive patient.

c) Non-infectious / Non-neoplastic diseases: lymphoproliferative disorders

Lymphocytic interstitial pneumonitis (LIP)

Lymphocytic interstitial pneumonitis (LIP) is a lymphoproliferative disorder occurring more commonly in immunocompromised patients, mainly those with AIDS. It causes diffuse infiltration of pulmonary lymphatics, resulting in slowly progressive dyspnea and cough. It is associated with infiltration of the parotid glands, liver and bone marrow.

It is more common in children than in adults.

Appearances on chest radiography are reticular or reticulonodular infiltrates, predominantly in the lower zones, and consolidation. CT features include bilateral ground-glass opacity, poorly defined centrilobular nodules, subpleural and peribronchovascular nodules, air space consolidation, bronchiectasis, pleural thickening and lymphadenopathy [6].

Differential diagnosis with OI, mainly PCP, should be made by biopsy.

Bronchiolitis obliterans

Bronchiolitis obliterans with and without organizing pneumonia in the absence of infection is a rare cause of pulmonary disease in patients with AIDS.

Plain chest radiography and CT findings include bilateral areas of parenchymal consolidation or ground-glass infiltrate in a geographical distribution. Poorly defined nodular infiltrates, subtle diffuse reticular infiltrates or scattered centrilobular nodules may be less commonly observed [5].

Non-specific interstitial pneumonitis (NSIP)

Non-specific interstitial pneumonitis occurs in the immunosuppressed patient with or without AIDS in the absence of a detectable opportunistic infection or neoplasm. Its incidence ranges from 4.6 to 38% and it is more common in IVDAs.

The cause of NSIP is unknown, but various etiological agents have been suggested, including HIV itself.

In some cases the plain chest radiograph and CT scan may be normal or show diffuse interstitial infiltrate or bronchiectasis and less commonly alveolar infiltrate.

Diagnosis of NSIP should be considered when the patient fails to respond to treatment for infectious conditions.

Diagnostic trend according to the radiological pattern

Table 1 shows and correlates the most common imaging findings with the most likely causative conditions. Several pulmonary diseases in AIDS patients manifest as multiple nodules.

Depending on the size, distribution and morphological characteristics of such nodules, in addition to other radiological appearances, diagnosis of potential etiologies may be made. This is summarized in Table 2 [26] [27].

References

1. Huang L"Pulmonary manifestations of HIV. HIV InSite knowledge base chapter, May 1998.
2. Muntaner L, Leys M, Payeras A, Herrera M, Gutierrez A. Radiologic features of Rodococcus equi pneumonia in AIDS. Eur J Radiol 1997; 24(1): 66-70.
3. Rosen MJ. Pulmonary complications of HIV infection. Respirology (2007). Journal compilation Asian Pacific Society of Respirology.
4. Shah A, Ostrum BJ, Friedman AC. Interpretation of chest radiographs in AIDS patients: usefulness of CD4 lymphocyte counts. Radiographics 1997;17:47-58.
5. Mc Guinness G. Complicaciones pulmonares del paciente con SIDA. En: Naidich D (ed.) Torax TC y RM. Madrid: Ed. Marbán Libros, 2000: 465-504.
6. King LJ, Padley SP. Imaging of the thorax in AIDS. Imaging 2002;14:60-76.
7. Oh Yu W, Effmann E, Godwin D. Pulmonary infectations in inmunocompromise host: the importance of correlating the conventional radiologic appearance with the clinical setting. Radiology 2000;217: 647-656.
8. Gallant J, Ko A. Cavitary pulmonary lesions in patients infected with human inmunodeficiency virus. Clinical infection diseases 1996;22:671-682.
9. Shah R, Gupta S, Angeid-Backman E, O`Donnell J. Pneumococcal pneumonia in patients requiring hospitalization. AJR. 2000;175:1533-1536.
10. Thomas CF, Limper AH. Pneumocystis pneumonia. The New England Journal of Medicine. 2004;350:2487-2498.
11. Gifford SL. Pneumocystosis and HIV. HIV InSite knowledge base chapter, January 2006.
12. Kuhlman J. Pneumocystic infections: the radiologist's perspective. Radiology. 1996;198:623-635.
13. Franquet T, Giménez A, Hidalgo A. Imaging of opportunisticfungal infections in immunocompromised patient. European Journal of Radiology. 2004;51:130–138.
14. Boiselle PM, Crans Jr CA, Kaplan MA. The changing face of Pneumocystis carinii pneumonia in AIDS patients. AJR. 1999;172:1301-1309.
15. Mc Loud T, Naidich D. Thoracic disease in the immunocompromised patient. En: Federle M. (ed.) Radiology of the inmunocompromised patient. Philadelphia: Ed. WB Saunders, 1992: 525-555.
16. Franquet T, Mu?ller N, Gimenez A, Guembe P, et al. Spectrum of pulmonary Aspergillosis: histologic, clinical and radiologic findings. Radiographics. 2001;21:825-837.
17. Hung M, Tsai Y, Lee C, Yang C. Pulmonary cryptococcosis: Clinical, radiographical and serological markers of dissemination. Respirology. 2007; Journal compilation Asian Pacific Society of Respirology.
18. Mootsikapun P, Chetchotisakd P, Intarapoka B. Histoplasmosis and penicilliosis: comparison of clinical features, laboratoryfindings and outcome. Int J Infect Dis. 2006; 10(1):66-71.
19. Busi Rizzi E, Schinina V, Girardi E, Bibbolino C. Radiological patterns in HIV-associated pulmonary tuberculosis comparison between HAART-treated and non- HAART-treated patients. Clin Radiol. 2003;58(6):469-73.
20. Erasmus J, McAdams HP, Farrel MA, Patz EF. Pulmonary nontuberculous mycobacterial infection: radiologic manifestations. Radiographics. 1999;19:1487-1503.
21. Maycher B, O`Connor R, Long R. Computed Tomographic abnormalities in Mycobacterium avium complex lung disease include the mosaic pattern of reduced lung attenuation. Can Assoc Radiol J. 2000;51(2):93-102.
22. Waxman A, Goldie S, Brett-Smith H, Matthay R. Cytomegalovirus as a primary pulmonary pathogen in AIDS. Chest. 1997;111:128-134.
23. Mc Guinness G, Scholes J, Garay S, Leitman B, Mc Cauley D, Naidich D. Citomegalovirus pneumonitis: spectrum of parenchymal CT findings with pathologic correlation in 21 AIDS patients. Radiology. 1994;192:451-459.
24. Haramati L, Wong J. Intrathoracic Kaposi's Sarcoma in women with AIDS. Chest. 2000;117:410-414.
25. Bazot M, Cadranel J, Benayoun S, Tassart M, et al. Primary pulmonary AIDS-related lymphoma. Chest. 1999;116:1282-1286.
26. Edinburgh K, Jasmer R, Huang L, et al. Multiple pulmonary nodules in AIDS: usefulness of CT in distinguishing among potential causes. Ragiology. 2000;214:427-432.
27. Jasmer R, Edinburgh K, Thompson A, et al. Clinical and radiographic predictors of the etiology of pulmonary nodules in HIV-infected patients. Chest. 2000;117:1023-1030.